

Abdominal Compartment Syndrome: Physiologic Consequences and Clinical Management

William Schechter, MD, FCCS

Professor of Clinical Surgery

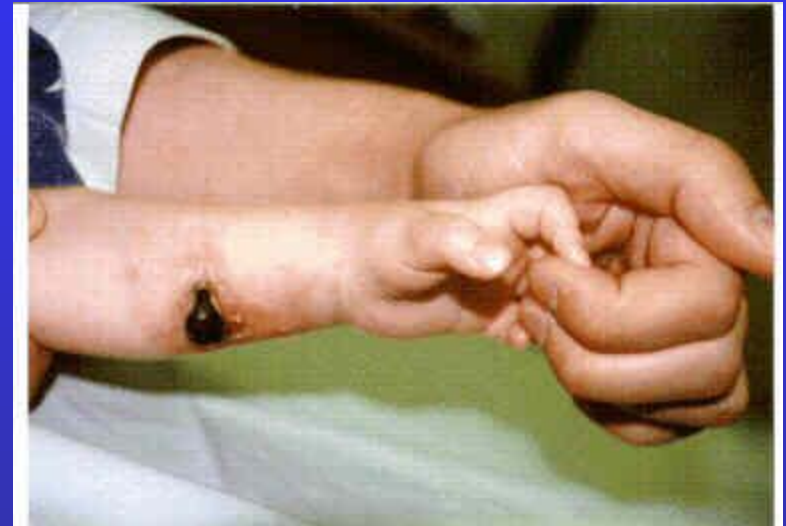University of California, San Francisco

Compartment Syndrome

*Elevated pressure within a closed
anatomic space compromising
capillary perfusion*

Examples of Compartment Syndrome

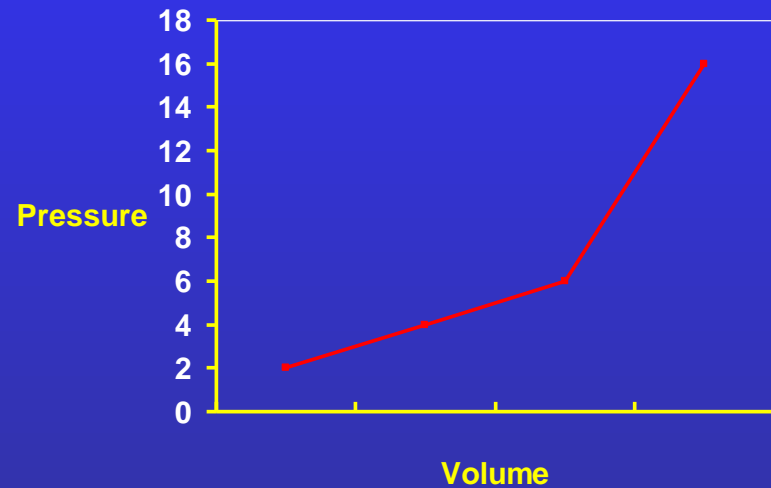
- Extremity Injury
- Circumferential Burn
- Tight Cast
- Intra-cranial Hypertension
- Abdominal Compartment Syndrome

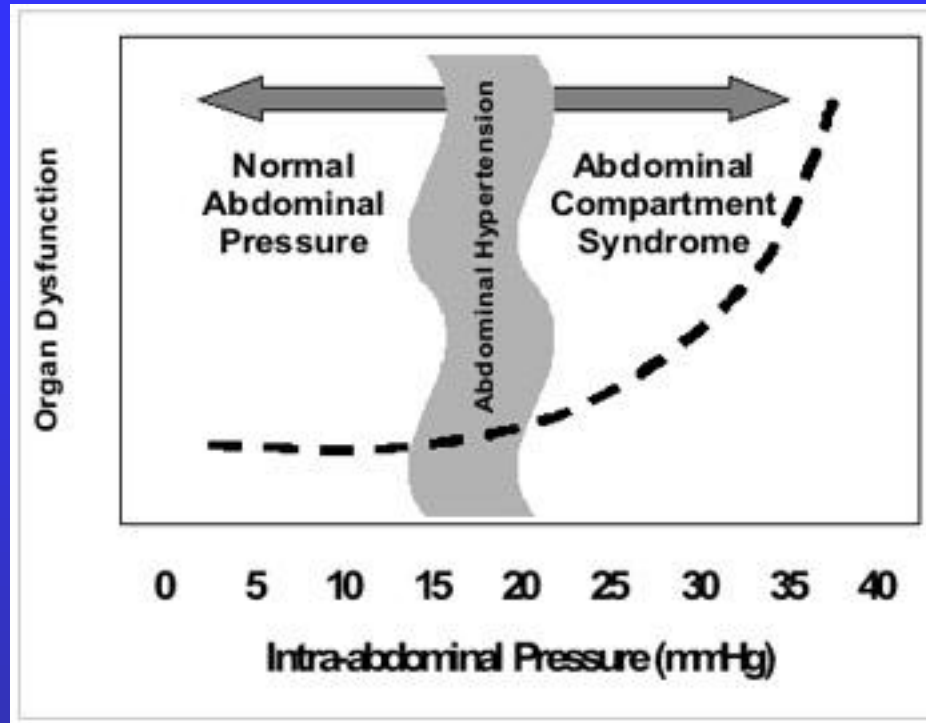


Volkmann's Ischemic Contracture
<http://www.wheelessonline.com/image2/volk1.jpg>

Intracranial Pressure

- Monroe-Kelly Doctrine
- $CPP = MAP - ICP$

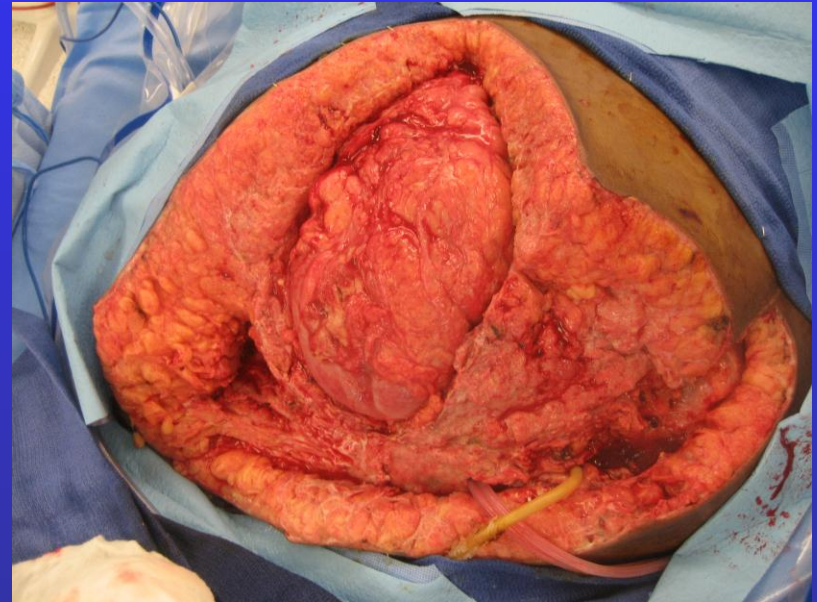



$$APP = MAP - IAP$$

Intra-abdominal Hypertension

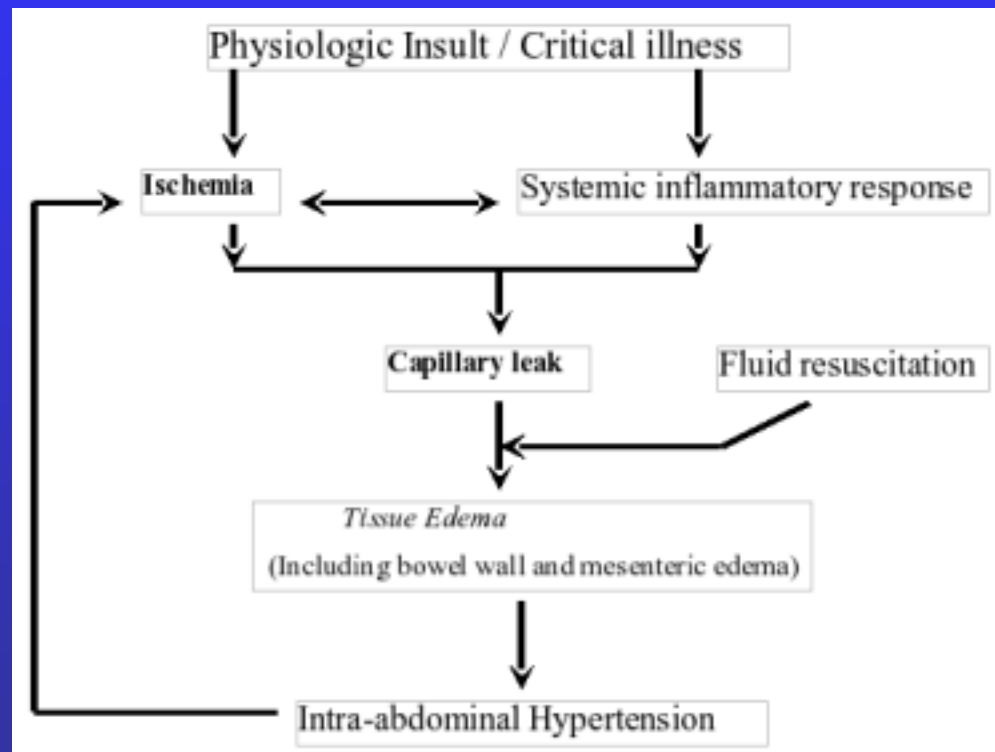
- Tissue Edema
(Bowel,
Retroperitoneum)
- Fluid Collecting
in Peritoneal
Cavity



Abdominal Compartment Syndrome

Organ Failure due to Intra-abdominal
Hypertension (IAH)

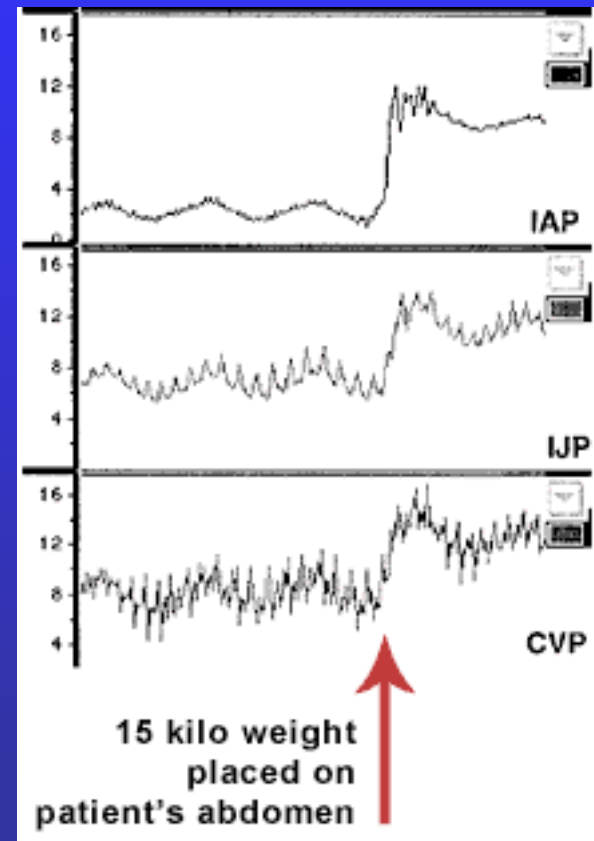
Pathophysiology of Abdominal Compartment Syndrome



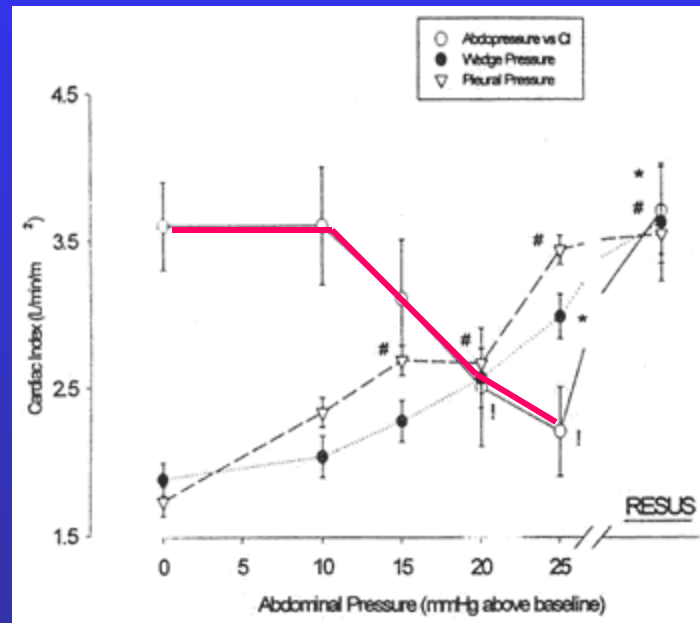
Physiologic Consequences

Cardiac Effects

- Increased CVP
- Decreased Preload



Cardiac Output vs Intra-abdominal Pressure

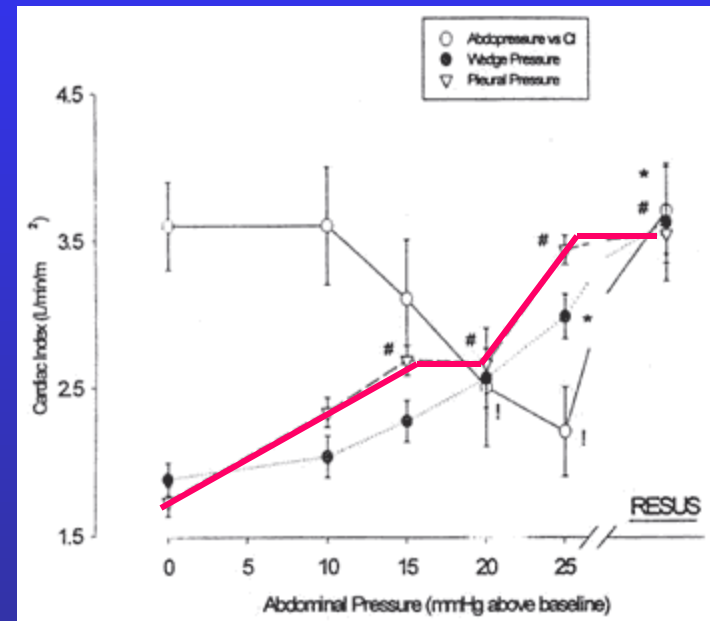


Ridings et al. Surg Forum 1992;45:74-76

Pulmonary Effects

Pleural Pressure and IAP

- Increased IPP
- Increased PAP
- Decreased TLC
- Decreased FRC
- Decreased Chest Wall Compliance



Ridings et al. Surg Forum 1992;45:74-76

Renal Effects of IAH

- vena cava compression
- Renal venous hypertension
- Decreased CO
- Glomerular Filtration Gradient = $MAP - 2 \times IAP^*$

*Effect of IAP on both Proximal tubular pressure and glomerular filtration pressure

Cullen DJ et al. Crit Care Med 1989;17:118-21

<http://www.abdominal-compartment-syndrome.org/acs/renal.html>

Gut Effects of IAH

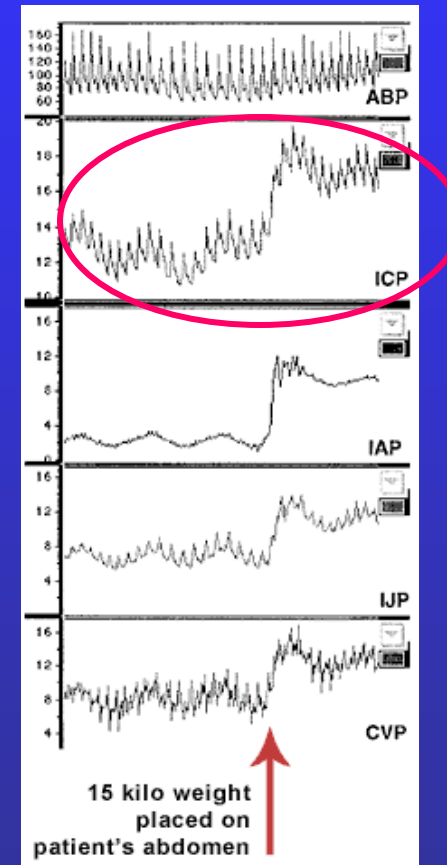
- Venous congestion
- Direct compression on mesenteric and hepatic capillaries
- Decreased CO
- Hypoxia

Diebel LN, Dulchavsky SA, Wilson RF. J Trauma 1992;33:45-8

Diebel LN, Dulchavsky SA, Brown WJ. J Trauma 1997;43: 852-5.

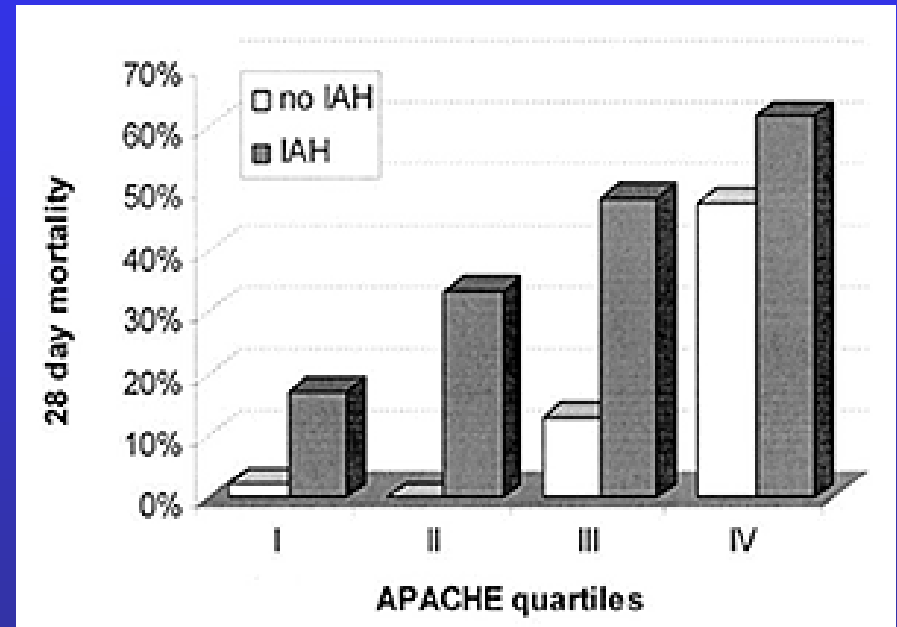
Effect if IAH on ICP

- Increased ICP
- Decreased CPP
- Consider decompressive laparotomy



Effect of IAH and ACS on Outcome

- Patients with IAH had increased mortality
- The mortality rate was significant *even* in patients with low APACHE scores



Grading of IAH

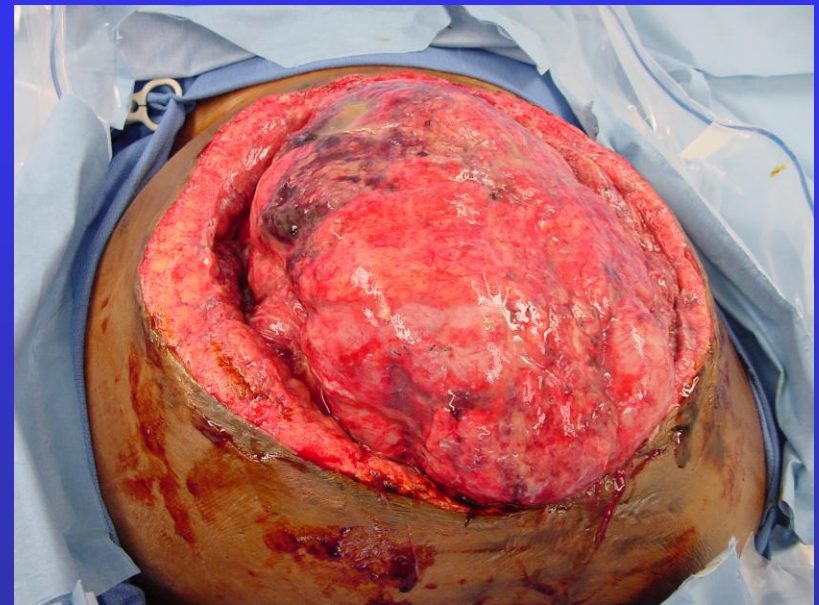
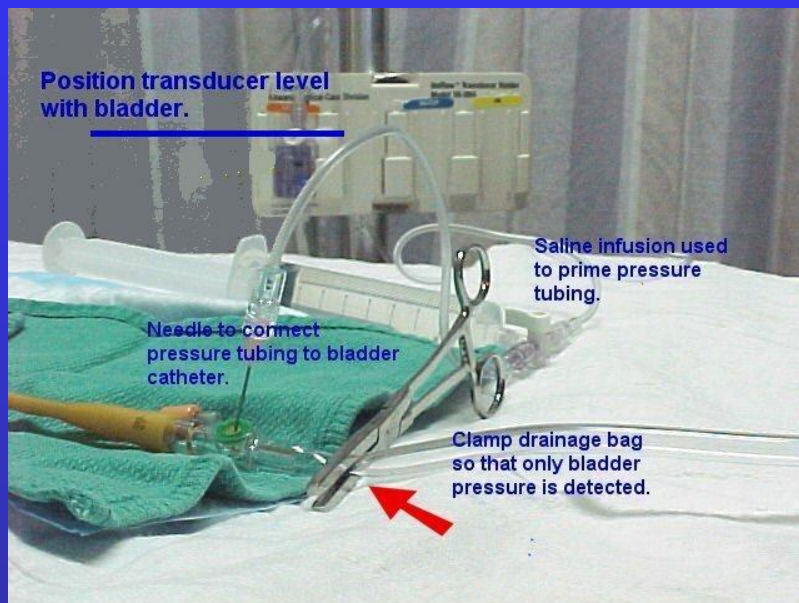
Grade	IAP	Rx
I	12-15 torr	Non-operative
II	15-20 torr	Non-operative
III	21-25 torr	Consider decompression
IV	>25 torr	Decompressive Laparotomy

Cheatham ML, Malbrain ML. Acta Clin Belg Suppl 2007;1:98-112
Teicher MJ, Pasquale ME, Cipolle MD Abdominal Compartment SyndromeMD Consult 2008; <http://www.mdconsult.com/das/article/body/103509574-2/jorg=journal&source=&sp=20724123&sid=0/N/646618/1.html?issn=1524-153X>

Non-operative Management

- Sedation
- Analgesia
- Intestinal decompression
- Paracentesis
- Neuromuscular blockade
- Judicious fluid resuscitation

Abdominal Compartment Syndrome



Bladder Pressure as Surrogate for
Intra-abdominal Pressure

Decompressive Laparotomy

Malbrain ML, Deeren DH. Crit Care
2006;10:R98

Open Abdomen Management

- A variety of different clinical scenarios
- Outcome and physiologic consequences different depending on clinical situation
- No scaling system yet described to allow comparison of different studies

Is there evidence that Decompressive Laparotomy improves outcome?

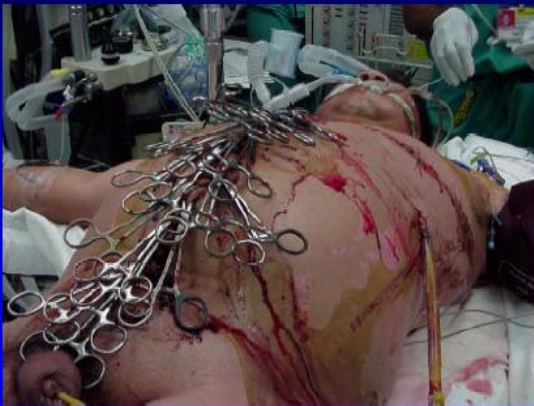Author	N	Mortality Rate Reduction
Ivatury et al.	77	36% -12%
Tao et al.	23	80% -16.7%
Cipolla et al.	17	73% - 5.9%

Options for Temporary Wound Coverage

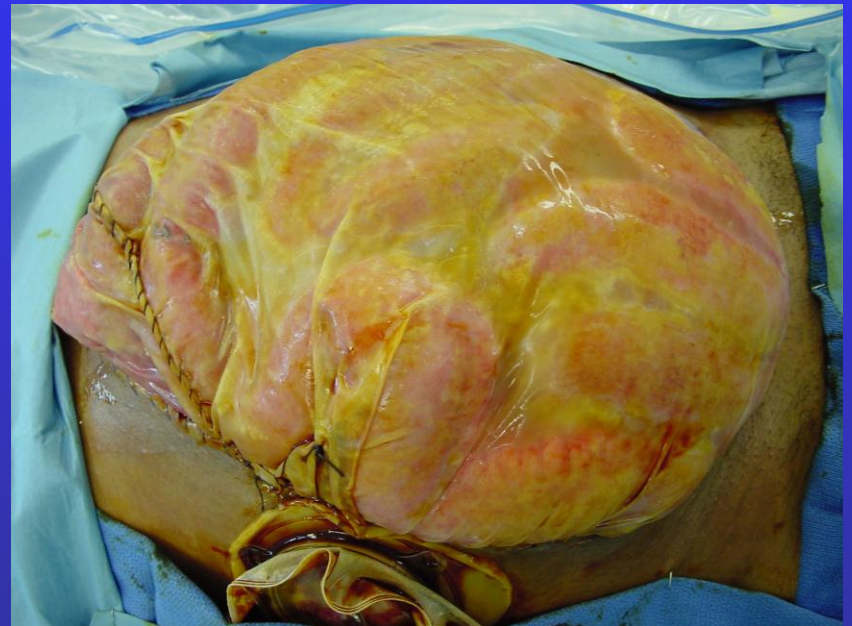- Skin-only Closure
- Plastic Abdominoplasty
- Absorbable mesh
- Non-absorbable mesh with protection of underlying viscera
- Vacuum Pack
- Vacuum-assisted wound management

Temporary Abdominal Closure

Towel Clip Closure

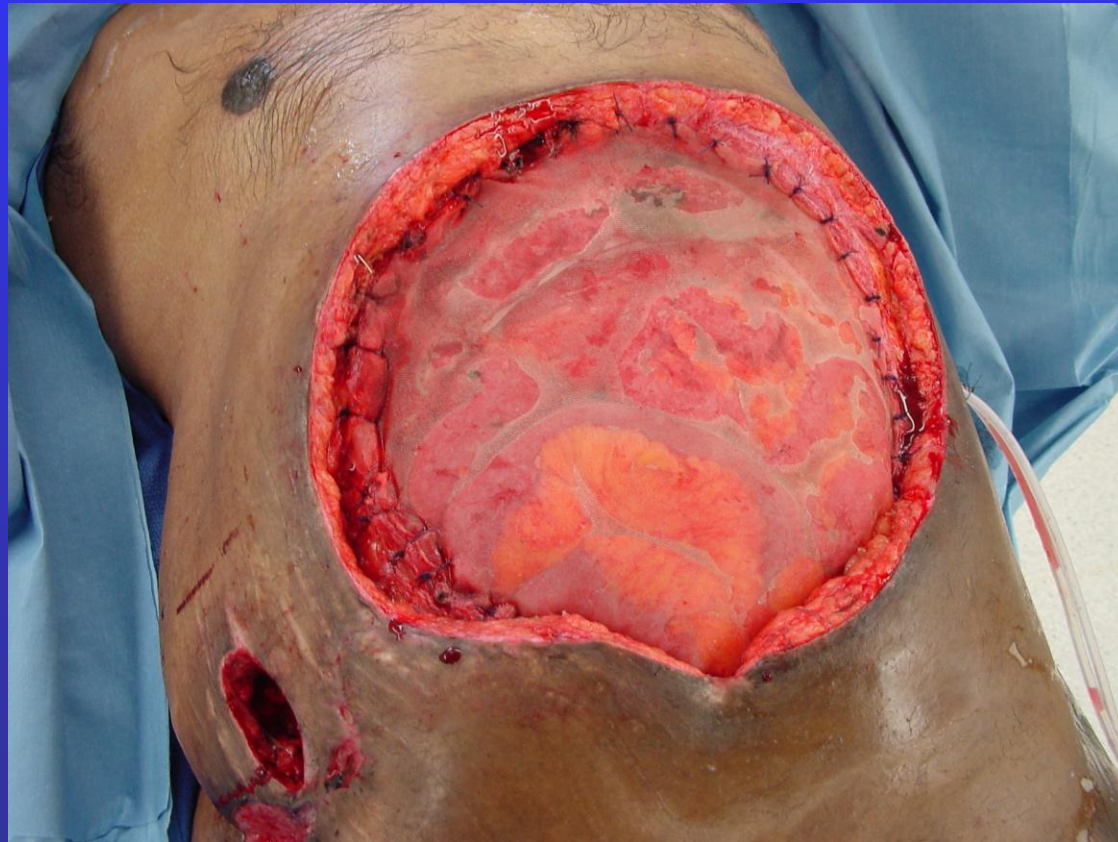

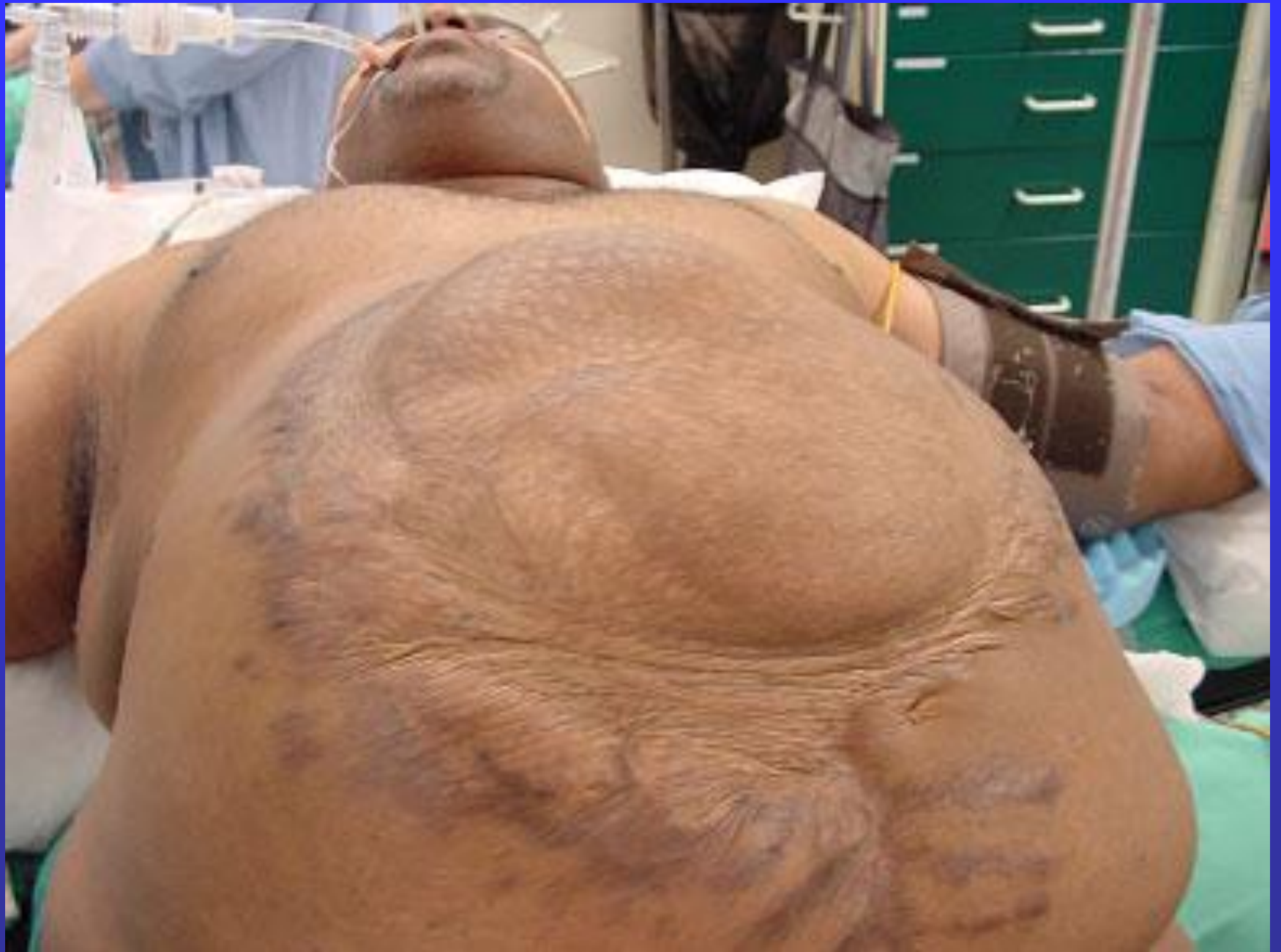Temporary Skin Closure



Plastic Silo

Absorbable Mesh





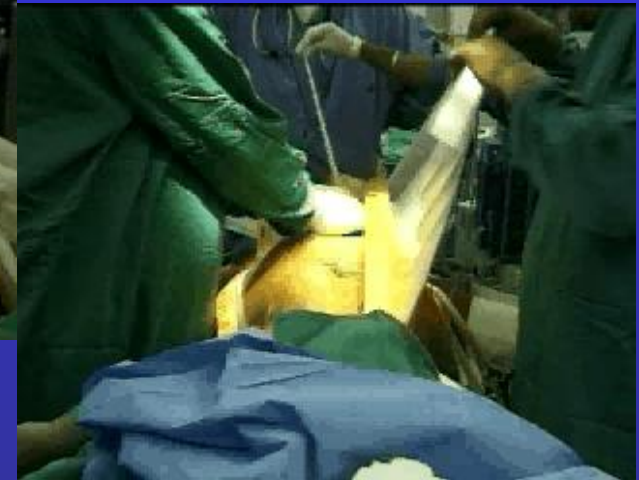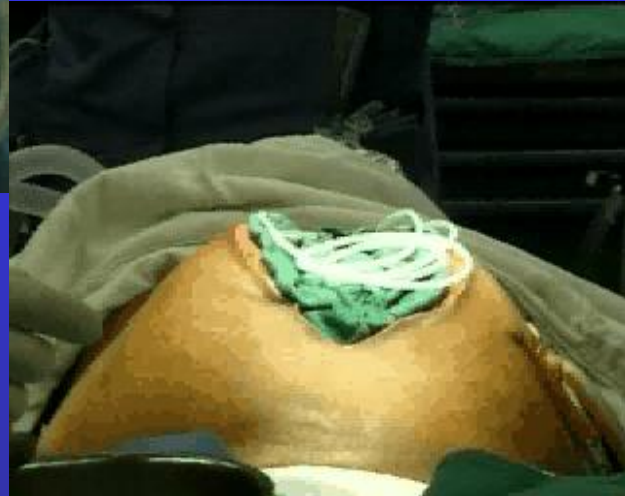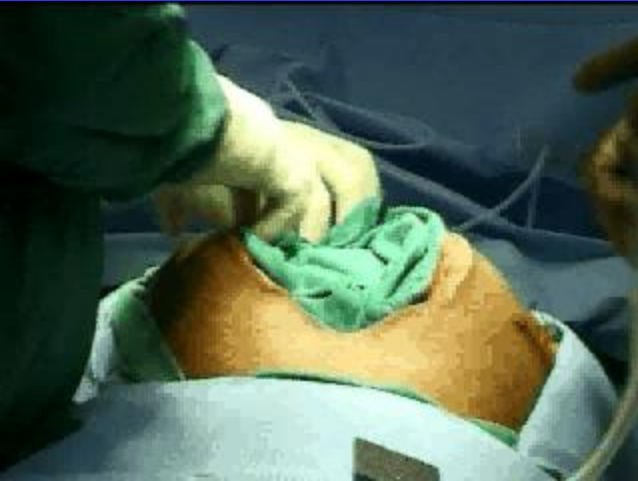The “VAC-PAC” Dressing

- Plastic Sheet covering the bowel
- Surgical Towel placed over the plastic
- Compression of the abdominal contents
- Control of fluid losses - suction drains

Brock WB, Barker DE, Burns RP. Temporary Closure of Open Abdominal Wounds: The Vacuum Pack. *Am Surg* 1995;61:30-35

Barker DE, Kaufman HJ, Smith LA, et al. Vacuum Pack Technique of Temporary Abdominal Closure: A 7 year experience with 112 patients. *J Trauma* 2000;48:201-207.

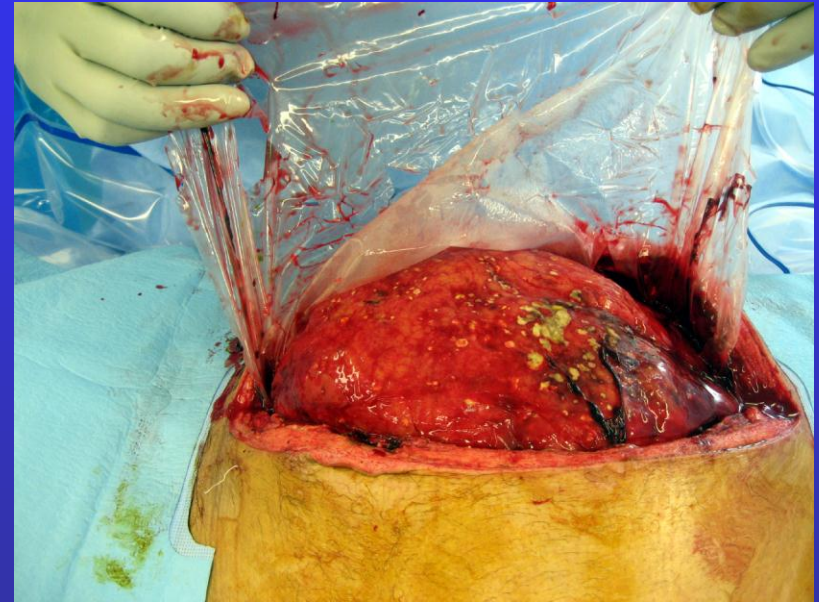
The “VAC-PAC” Dressing



Pictures courtesy of Michael Rotondo, MD

Unintended Fortuitous Consequence of the Vac-Pac

- *The plastic sheet delays adhesion formation between the visceral block and the abdominal wall*

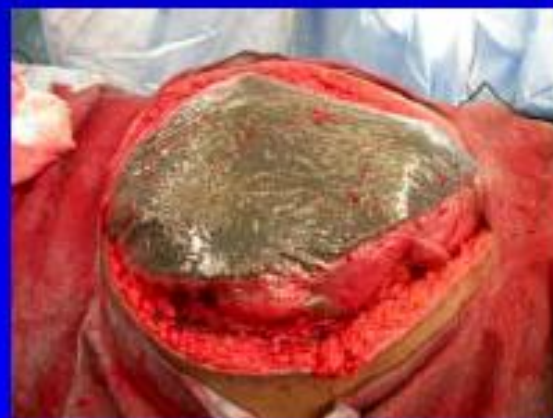
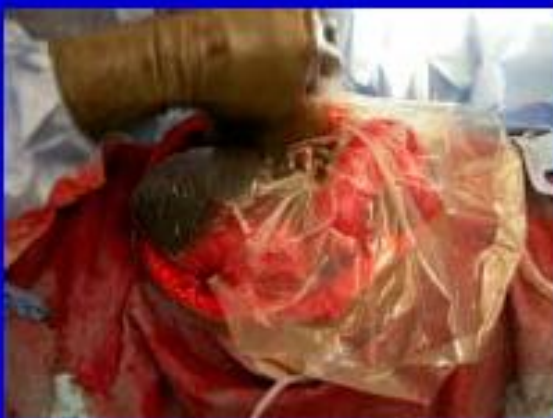
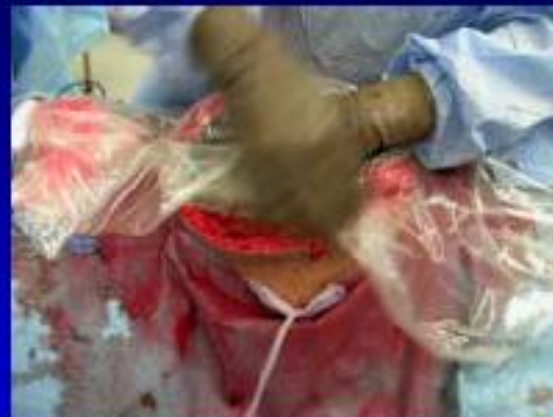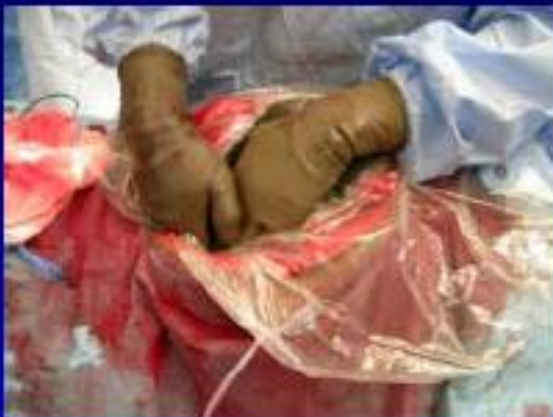Vacuum-Assisted Wound Closure

Garner GB, et al. Vacuum-assisted wound closure provides early fascial re-approximation in trauma patients with open abdomens. *Am J Surg.* 182:630, 2001.

- **2001 Vacuum Assisted Wound Closure (VAWC)**
 - VAWC device (KCI Vacuum-Assisted Closure, San Antonio, TX)
 - 14 trauma patients, dressing changed q 48 hours
 - Achieved delayed fascial closure in 13 (92%)
 - 9 ± 1.9 days
 - $2.8 \pm$ VAWC dressing changes
 - 2 wound infections
 - No fistulas or evisceration

Current Approach


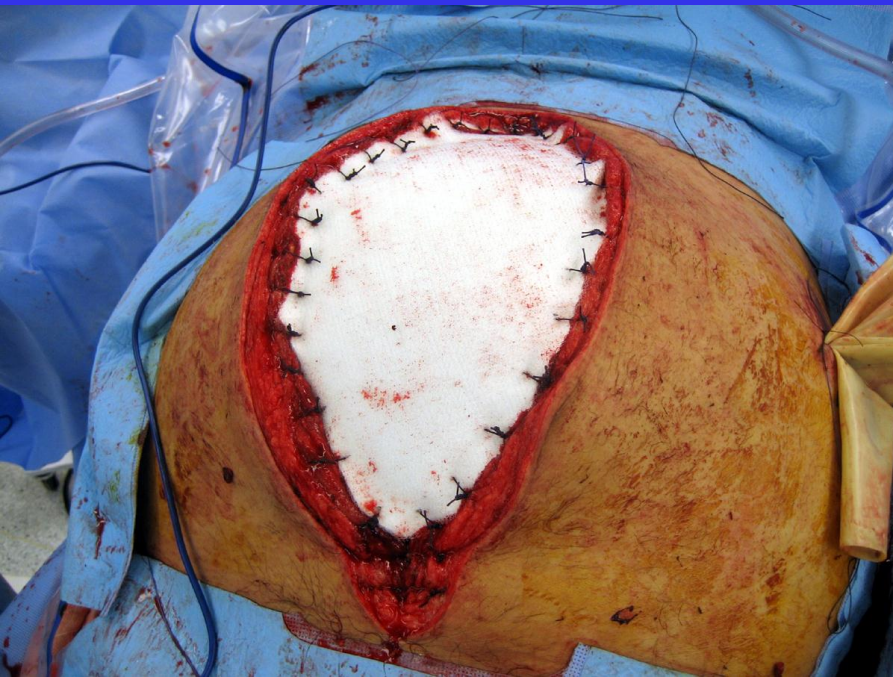


Principles Leading to a Revolution in the Management of the Open Abdomen

- Preservation of the Peritoneal Cavity
- Vacuum Assisted Wound Management
- Prevention of lateral fascial retraction
- Progressive graded abdominal closure
- Biologic Dressings

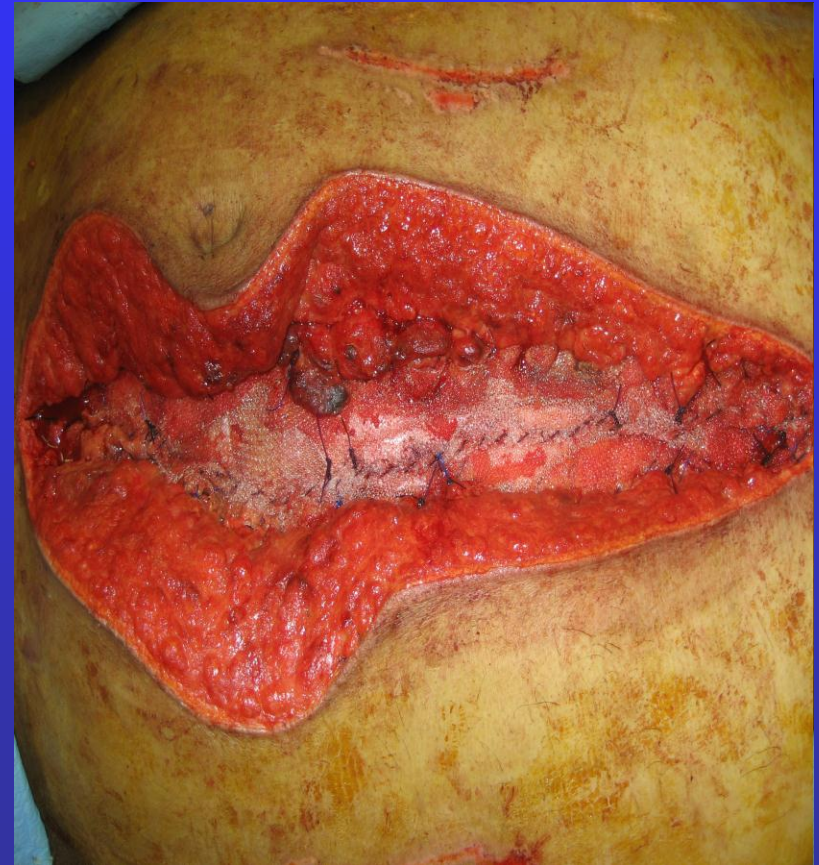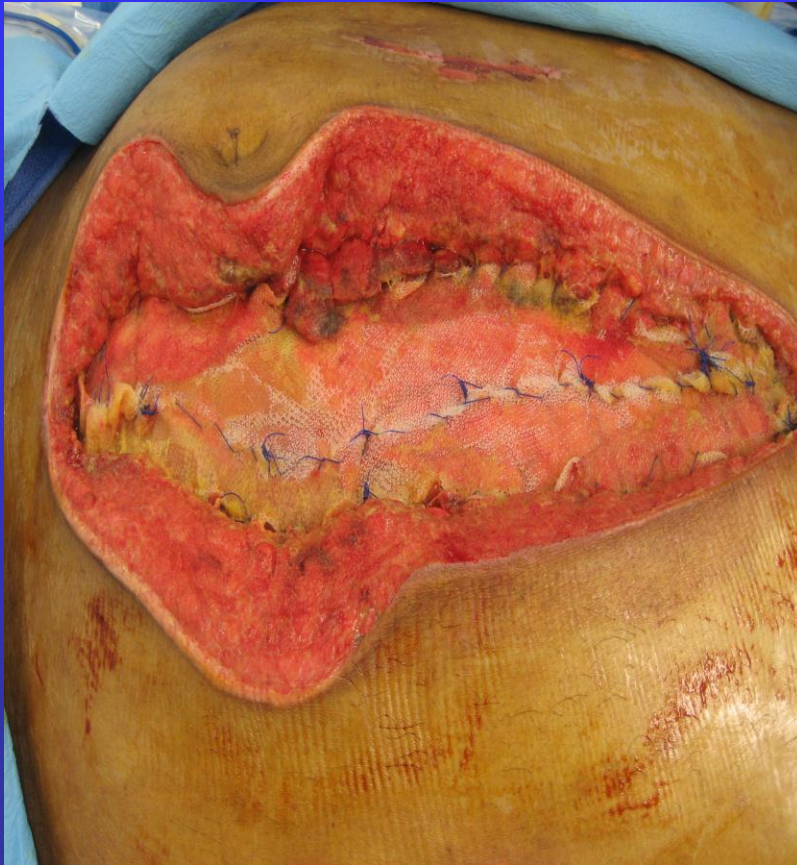Scott BG, Feanny MA, Hirshberg A. Early definitive closure of the open abdomen:
A quiet revolution. Scand J Surg 2005;94:9-14.

Prevention of Lateral Fascial Retraction

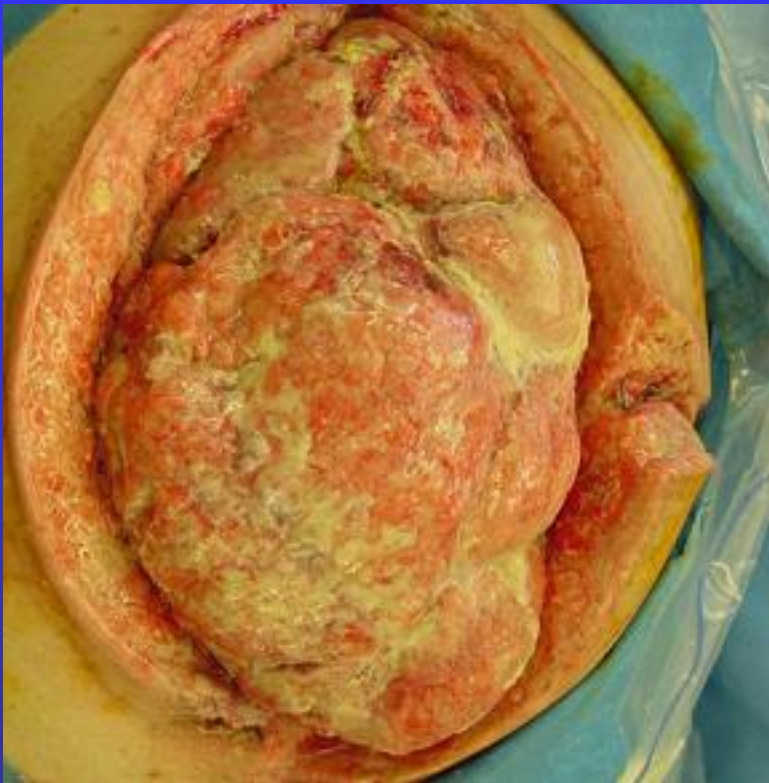

Marlex outside, PTFE inside

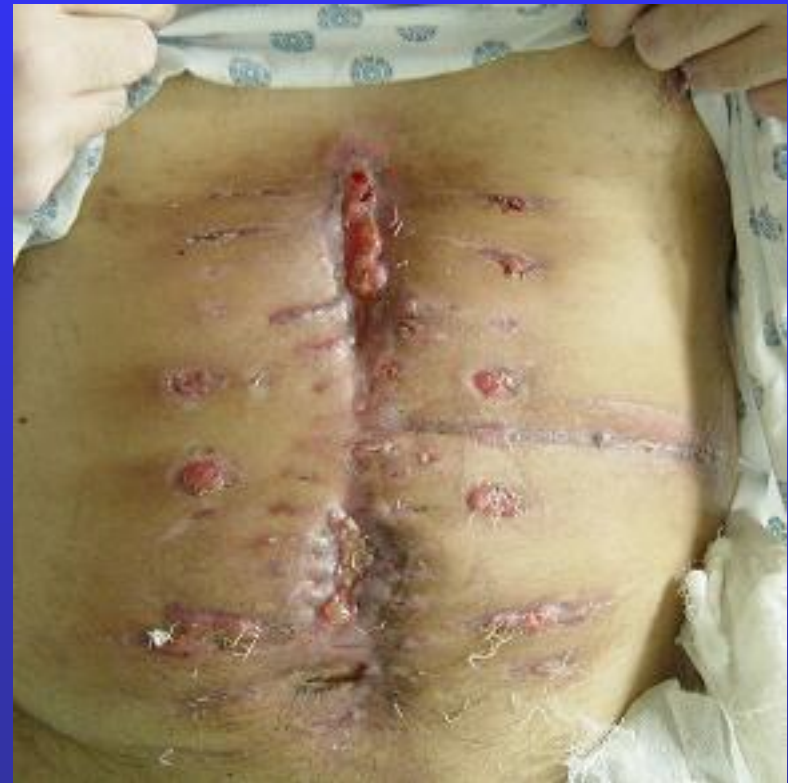“Reefing” Marlex to slowly approximate the fascia



Delayed Primary Fascial Closure



Peritonitis

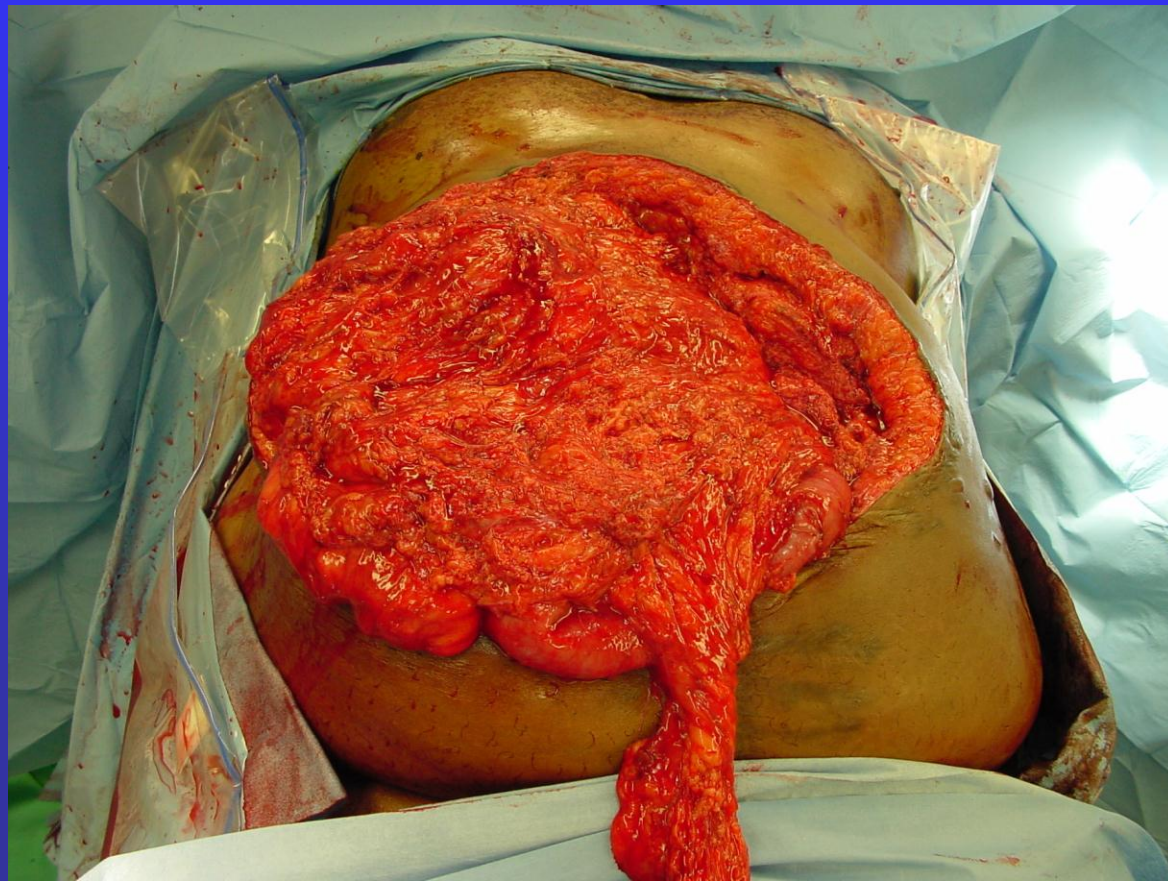


Delayed primary fascial closure
Approximately 6 weeks later

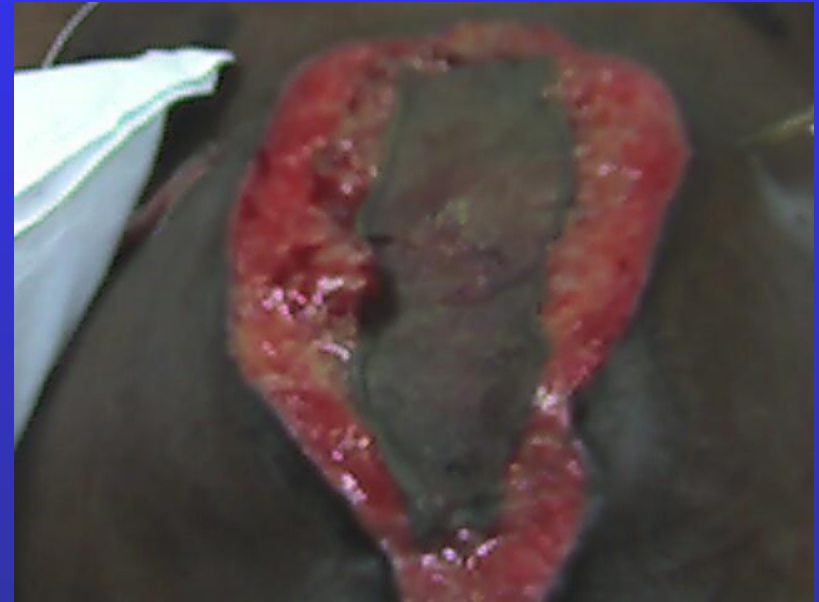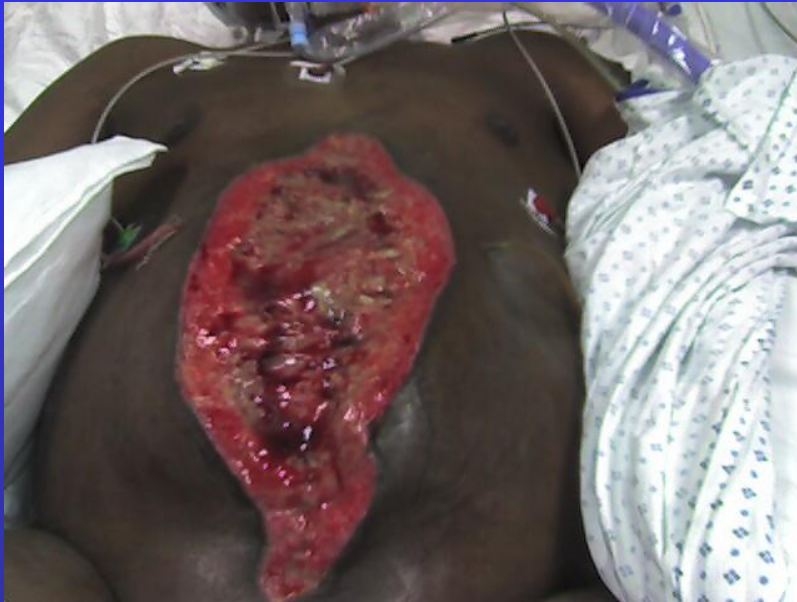Options for “Biologic Dressings” for the Open Abdomen

- Advancement Skin Flaps
- Homologous Split Thickness Skin Graft
- Autologous Split Thickness Skin Graft
- Acellular Dermal Matrix
- Myofascial Advancement Flaps
- Rotation Skin and Muscle Flaps
- Free Muscle flaps

Omentum as a Biologic Dressing

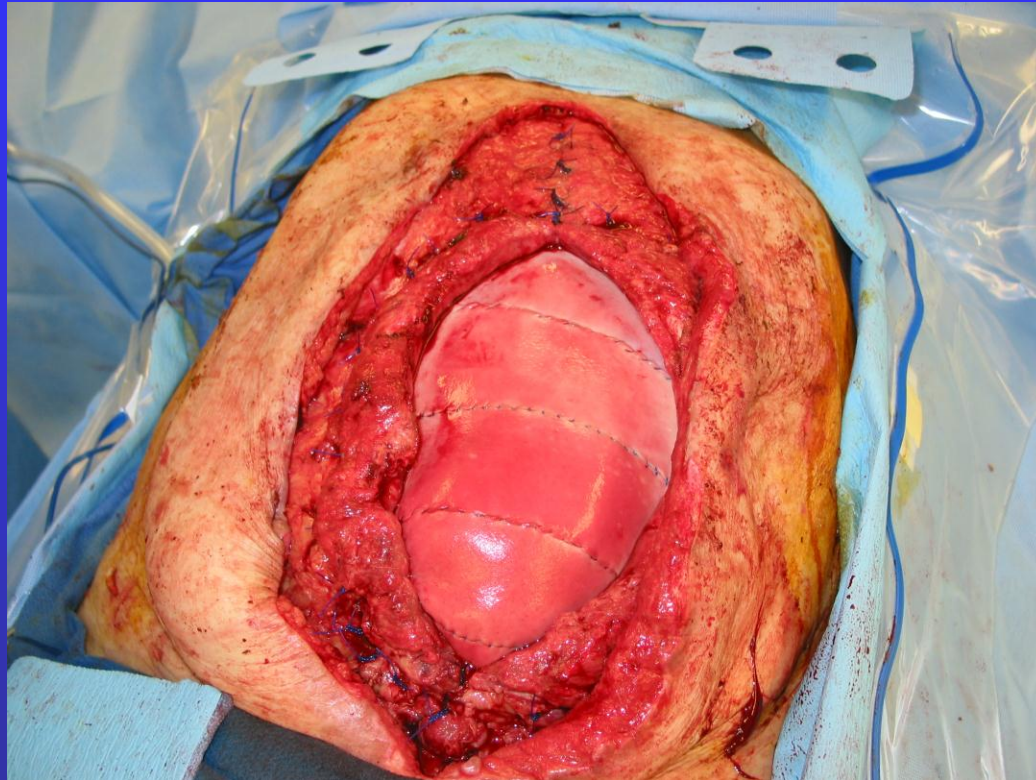


Homologous Split Thickness Skin as a Biologic Dressing



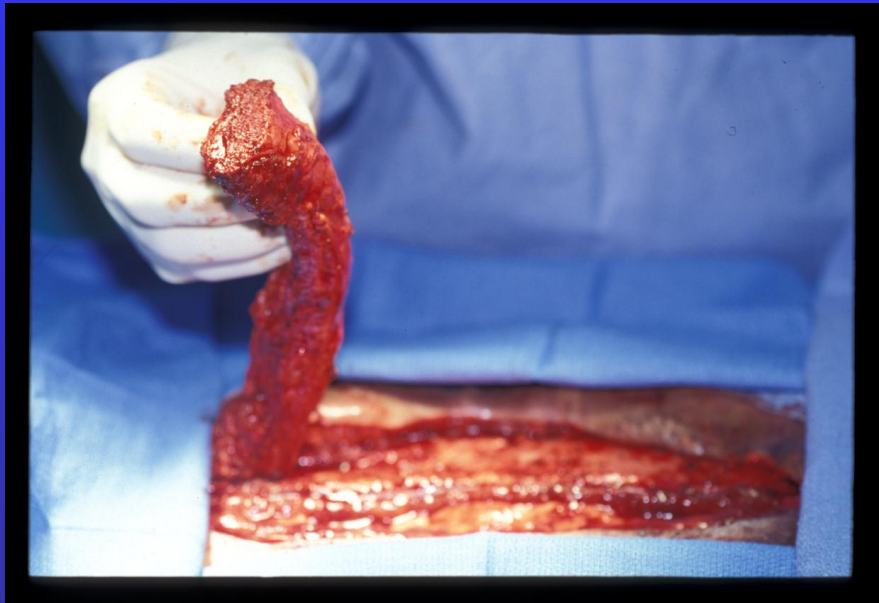
Jamshidi R, Schechter W. Biological dressings for the management of enteric fistulas in the open abdomen: a preliminary report. *Arch Surg.* 2007;142:793-6.

Acellular Dermal Matrix as a Biologic Dressing

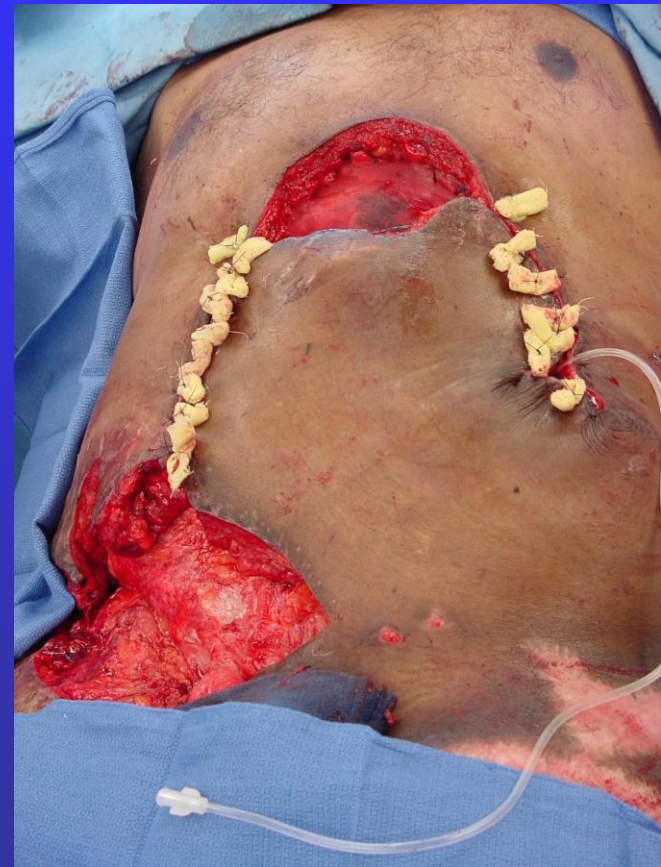

Scott BG, Welsh FJ, Pham HO, et al. Early aggressive closure of the open abdomen.
J Trauma 2006;60:17-22.

Skin and Muscle Flap Coverage



Rectus Abdominus Muscle Transposition
Flap



Delayed Random Rotation Skin Flap

Preferred Approach to Open Abdomen Management

	Recommendation	Grade of Recommendation
1.	Leave fascia open and close skin over viscera if possible	I B
2.	Preserve the omentum, if possible, for visceral coverage	I B
3.	Use a Vac-Pac coverage of the open abdomen after the initial decompressive laparotomy	II A

Preferred Approach to Open Abdomen Management

Recommendation		Grade of Recommendation
4.	At the second procedure, cover viscera with cadaver skin if no omentum and a prolonged open abdomen is anticipated	II C
5.	Ensure that there is “gutter to gutter” visceral coverage with a fenestrated plastic sheet	I B
6.	Use non-absorbable mesh sutured to fascia to prevent lateral fascial retraction	I C
7.	Reef the mesh together to approximate the fascial edges slowly at serial Wound V.A.C. Dressing changes in the OR.	I B

Editorial Opinion

A cautionary note: the use of vacuum-assisted closure systems in the treatment of gastrointestinal cutaneous fistula may be associated with higher mortality from subsequent fistula development

KEYWORDS:

Gastrointestinal
cutaneous fistula;
Mortality;
Vacuum-assisted
closure systems

Abstract. During the past several years, vacuum-assisted closure (VAC) systems have been increasingly used in the treatment of gastrointestinal cutaneous fistulas, particularly those associated with open abdomen. Recently, I experienced 2 cases in which the original fistula closed after treatment by the VAC system. However, these patients, who had exposed bowel, developed an additional fistula that required surgery. In a recent article from an intestinal-failure unit in the United Kingdom, Rao et al¹ reported on a series of 29 patients treated with VAC, 6 of whom developed new gastrointestinal cutaneous fistulas. Four of these 6 patients died. My own experiences, plus the report of Rao et al,¹ suggest the possibility that the use of the VAC system in patients with exposed bowel and an open abdomen may be associated with subsequent fistula development. Although the numbers are small, it also raises the question that development of a fistula in a patient treated with VAC may result in higher mortality.

© 2008 Elsevier Inc. All rights reserved.

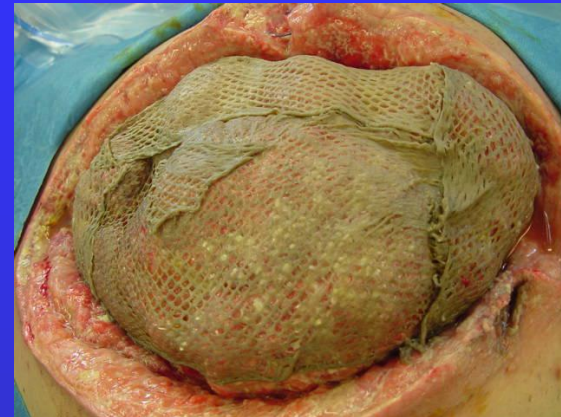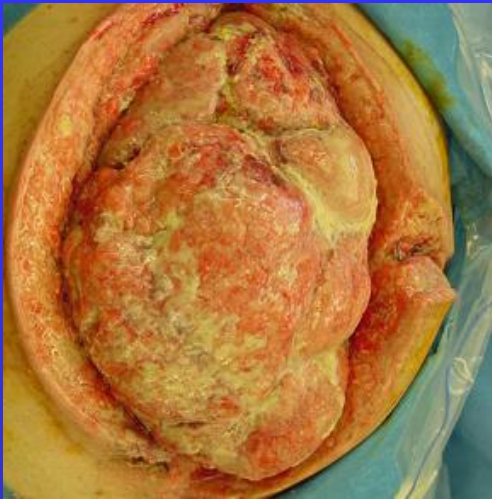
The use of vacuum-assisted closure (VAC) systems for the past decade in the United Kingdom, and for a somewhat shorter period of time in the United States, has become an essential part of the care of patients with open abdominal wounds. Although VAC has not yet been approved by the United States Food and Drug Administration for all of the situations in which it is used, the use

semioclusive drape is then placed over the entire wound, and a small hole is fashioned through which an 18F tube can be inserted, which transmits suction from a vacuum pump that creates negative suction ≤ 125 mm Hg. If the bowel is exposed, a somewhat different foam and tubing is used, presumably to protect the bowel. The dressing is changed every 72 hours with the patient under sedation.

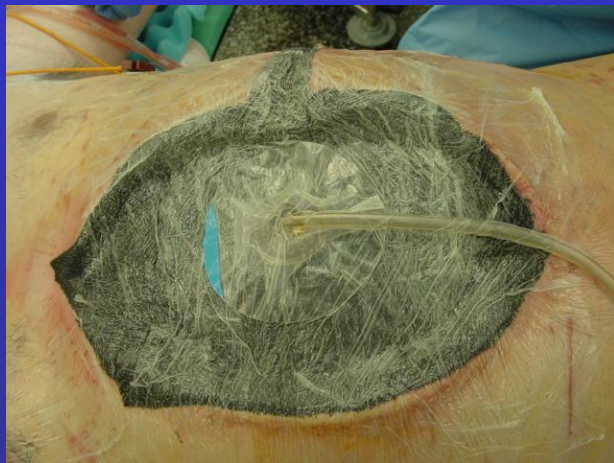Problem of “Entero-atmospheric” Fistula

- Absence of overlying soft tissue with good blood supply precludes spontaneous healing
- Exposed abdominal viscera predisposes to development of additional holes in the GI tract
- Complex wound, catabolism, high morbidity and mortality

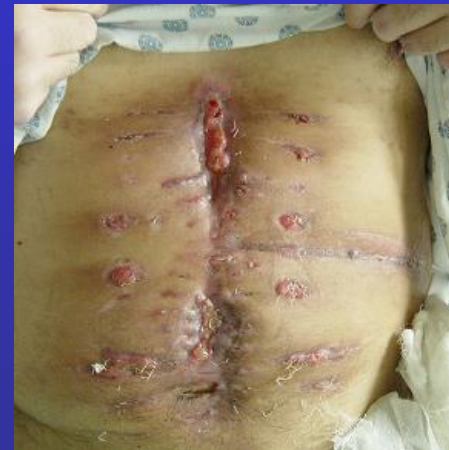Prevention of an Entero-atmospheric Fistula



Viscera Protection with Cadavre
Skin as a Biologic Dressing



Wound V.A.C.



Delayed Primary Closure of Wound

Summary

- IAH and ACS are relatively common problems
- Frequent monitoring of bladder pressures as a surrogate for IAP is standard of care
- Decompressive Laparotomy may be necessary for patients with IAP > 25 torr
- Access to the wound should be limited to senior surgeons